

Intractable parastomal bleeding in a portal hypertensive patient managed by direct sclerotherapy: a case report



Najmeh Aletaha, Niloofar Ayoobi
Yazdi,
Mohammad-Mehdi Mehrabinejad, Ali
Zare Dehnavi, Hadi Rokni
Yazdi

Introduction

Patients with a stoma have 5% chance of developing parastomal varices, which tend to repetitive massive and life-threatening hemorrhages.



Introduction

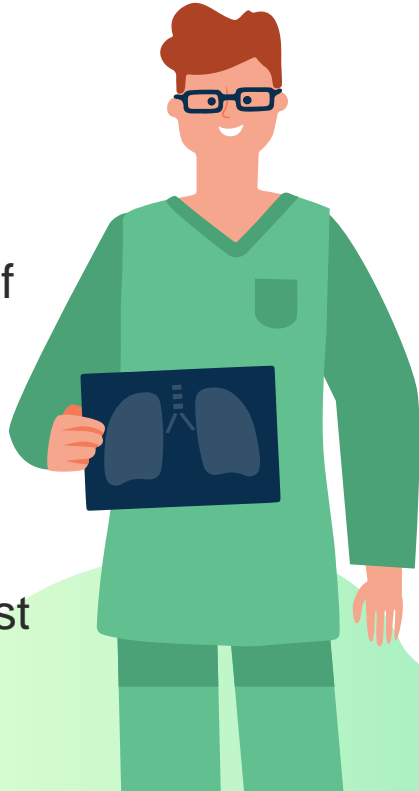
Treatment of choice in parastomal varices have not been established, while Transjugular Intrahepatic Portosystemic Shunt (TIPS) has been revealed as the most successful measure.



Identifying Information

Case report

A 52-year-old man was admitted to Imam Khomeini hospital for recurrent bleeding from the site of previous colostomy. The patient had a history of UC, PSC, cirrhosis, and underwent left hemicolectomy with a colostomy because of colon cancer in August 2018.



Case report.....

Surgery was followed by chemotherapy. Four months after surgery, bleeding started from the colostomy site, and it was exacerbated progressively. Hemoglobin value reached as low as 2 mg/dl in the last bleeding episode, due to the frequent blood losses, and the patient required several hospitalizations.



Patient Medical History



The patient's heart was arrested in the last bleeding episode and was revived via resuscitation and blood transfusions. Non-operative treatments and TIPS failed to control the symptoms. Color Doppler ultrasound showed a hepato-fugal flow.

Results

The direct antegrade technique, using Sodium Tetradecyl Sulfate (STS 1%) and glue-Lipiodol, was applied under ultrasonography guidance, and complete stoppage of bleeding was achieved. No immediate or late complication or follow-up recurrence were noted after 8 months.



Discussions



In case of hepato-fugal flow, direct percutaneous mesenteric parastomal venous access and sclerotherapy is a rapid and relatively safe procedure for parastomal variceal bleeding in unstable patients and in emergency situations.

Thanks



CREDITS: This presentation template was created by Slidesgo, including icons by Flaticon, and infographics & images by Freepik.